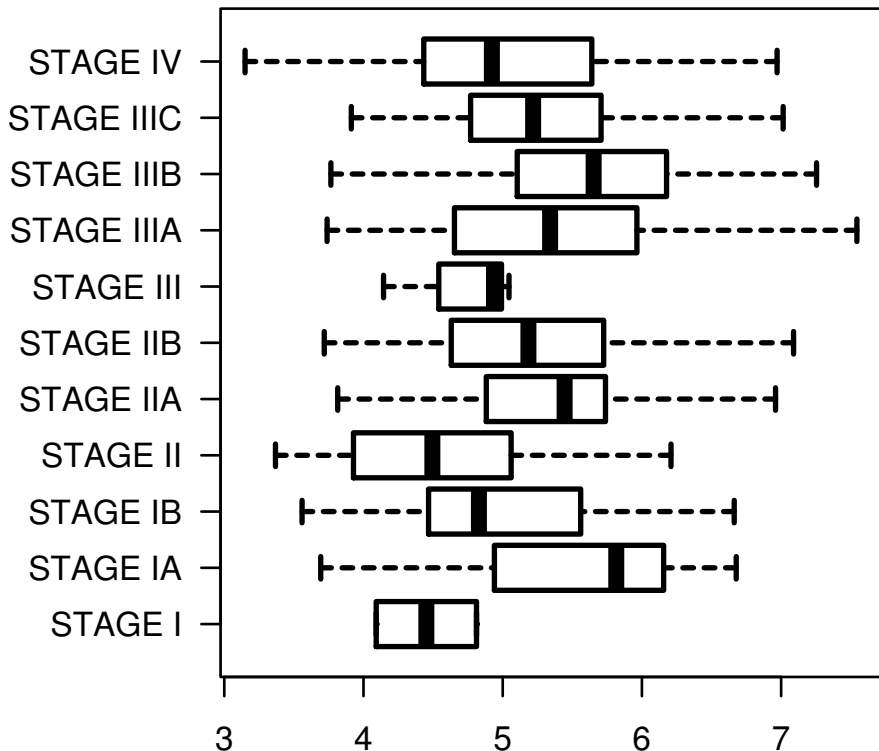


PATHOLOGIC_STAGE

HSA-MIR-101-2



log₂-EXPR

Kruskal-Wallis P = 6.06e-07