

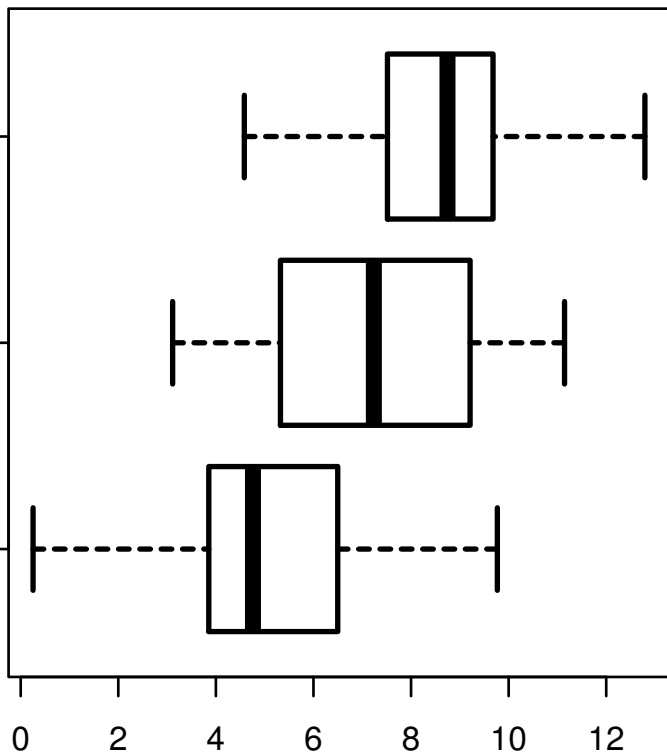
# SLC6A12|6539

STOLOGICAL\_TYPE

SEROUS  
ENDOMETRIAL  
ADENOCARCINOMA

MIXED SEROUS  
AND  
ENDOMETRIOID

ENDOMETRIOID  
ENDOMETRIAL  
ADENOCARCINOMA



log<sub>2</sub>-EXPR  
Kruskal-Wallis P = 2.98e-39