

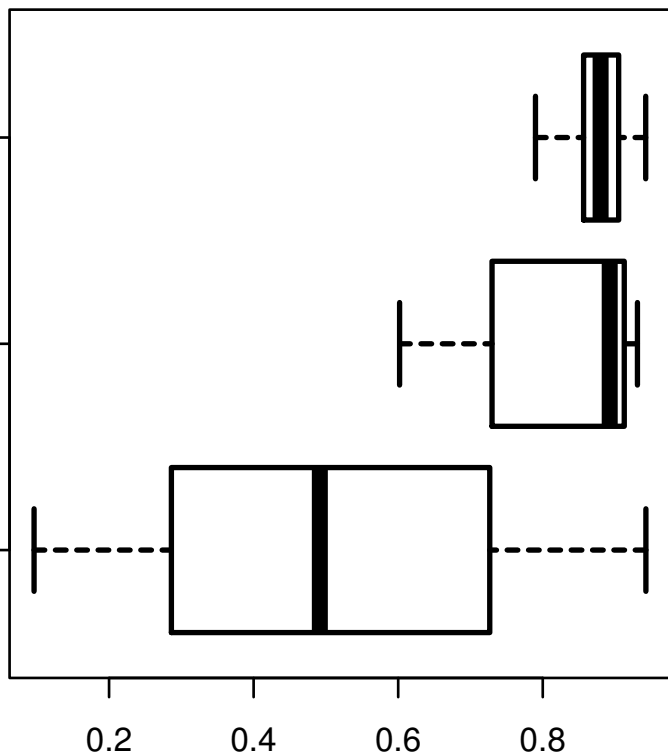
# LRRC36

STOLOGICAL\_TYPE

SEROUS  
ENDOMETRIAL  
ADENOCARCINOMA

MIXED SEROUS  
AND  
ENDOMETRIOID

ENDOMETRIOID  
ENDOMETRIAL  
ADENOCARCINOMA



log2-EXPR

Kruskal-Wallis P = 1.54e-32