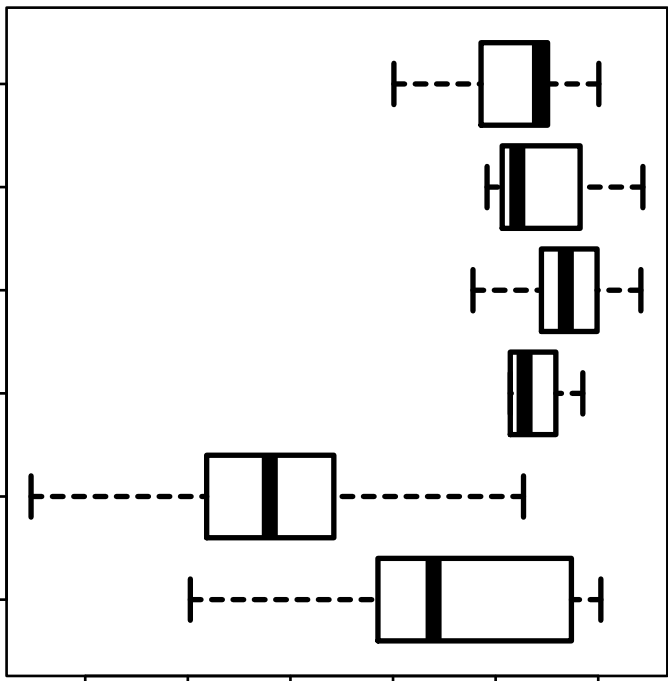


HR

STOLOGICAL_TYPE

MUCINOUS
ADENOCARCINOMA
OF
ENDOCERVICAL
ENDOMETRIUM
ADENOCARCINOMA
OF ENDOCERVIX
ENDOCERVICAL
TYPE OF
ADENOCARCINOMA
ENDOCERVICAL
ADENOCARCINOMA
OF THE USUAL
CERVICAL
TYPE
SQUAMOUS CELL
CARCINOMA
ADENOSQUAMOUS



0.3 0.4 0.5 0.6 0.7 0.8

log2-EXPR

Kruskal-Wallis P = 1.42e-20