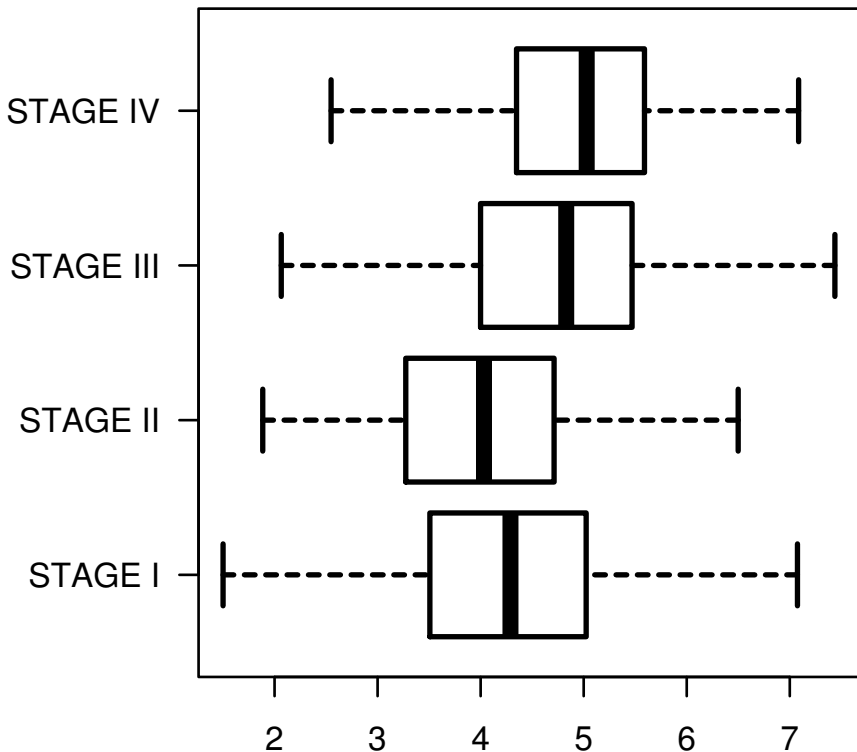


PATHOLOGIC_STAGE

HSA-MIR-365-1



log2-EXPR
Kruskal-Wallis P = 3.54e-13