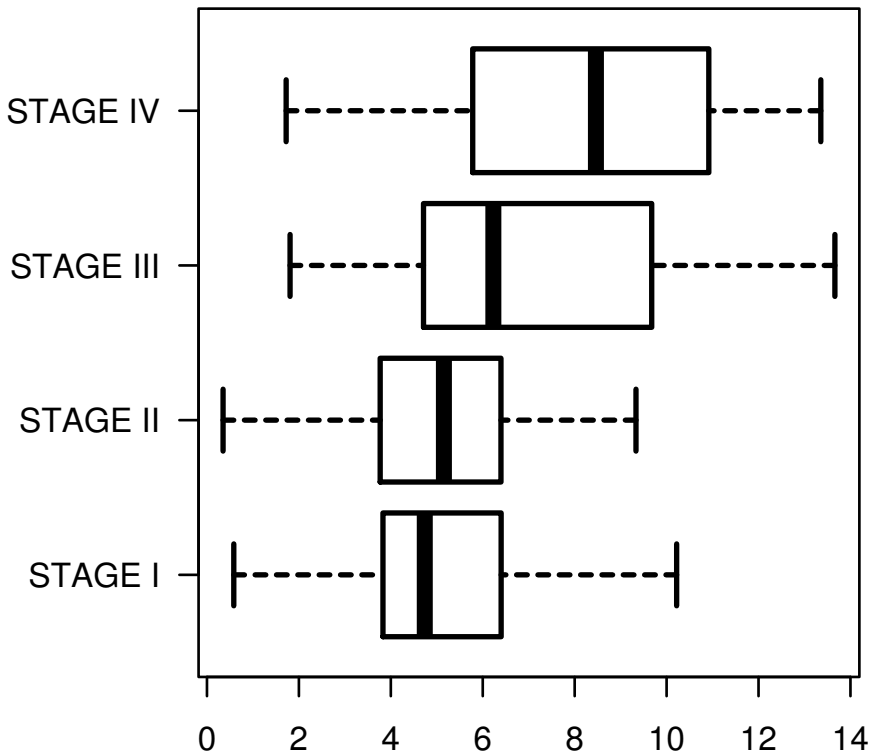


PATHOLOGIC_STAGE

IL20RB|53833



log2-EXPR
Kruskal-Wallis P = 2.2e-16