

# MID1IP1|58526

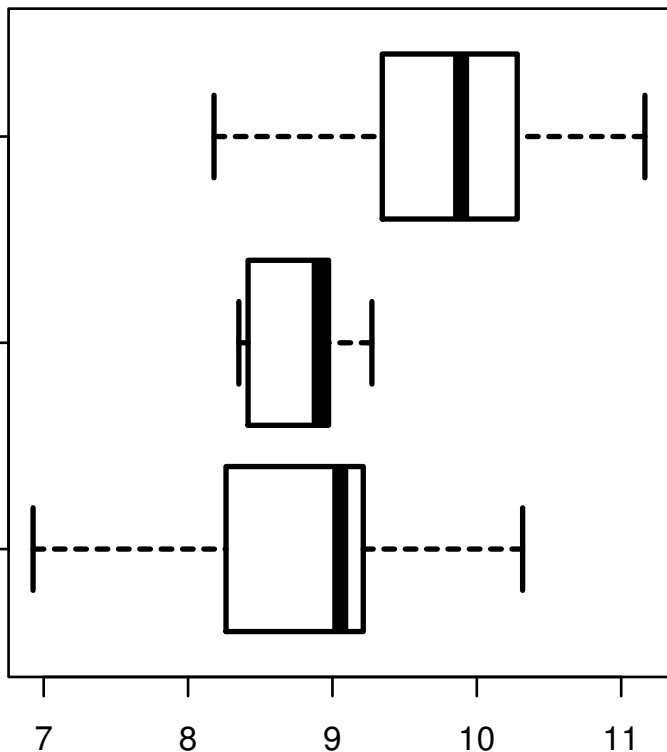
STOLOGICAL\_TYPE

PHEOCHROMOCYTOMA

PARAGANGLIOMA;  
EXTRA-  
ADRENAL

PHEOCHROMOCYTOMA

PARAGANGLIOMA



log2-EXPR

Kruskal-Wallis P = 7.69e-09