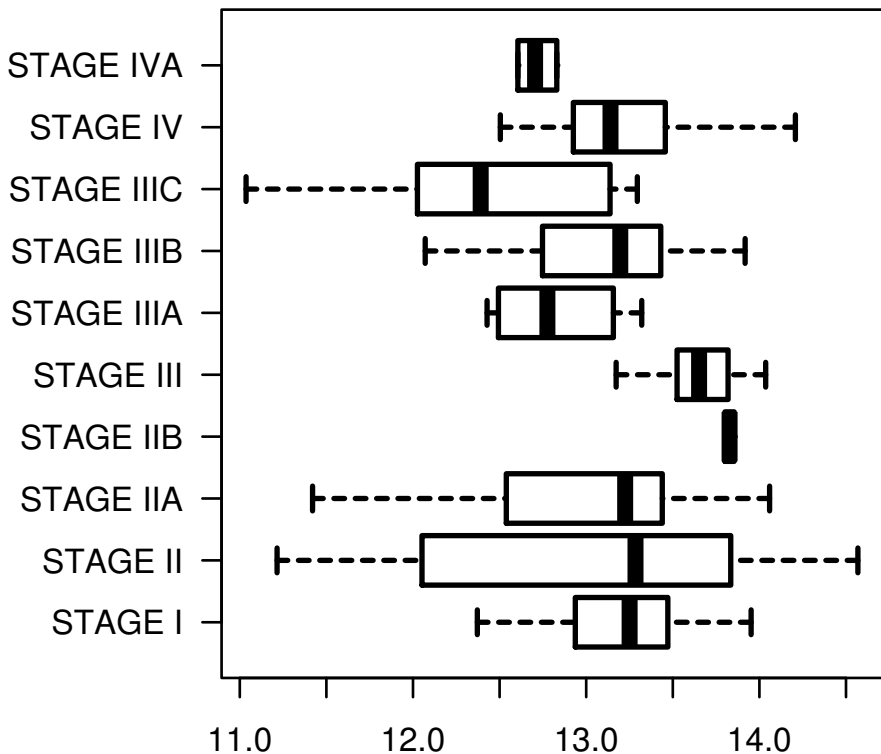


PATHOLOGIC_STAGE

HSA-MIR-194-2



Kruskal-Wallis P = 0.00333