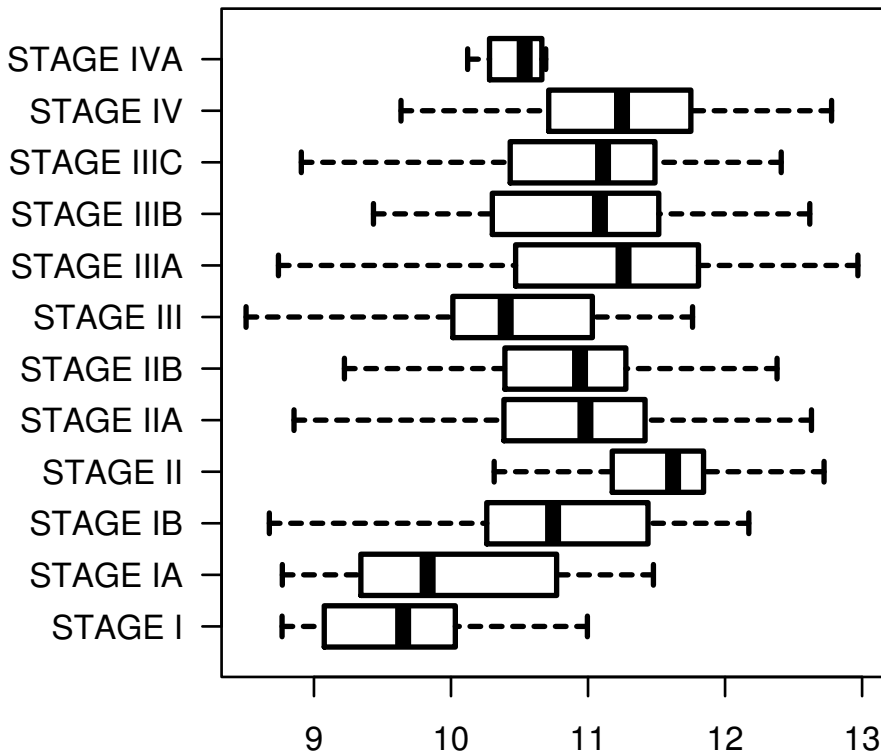


PATHOLOGIC\_STAGE

# HSA-MIR-199B



Kruskal-Wallis P = 4.49e-11