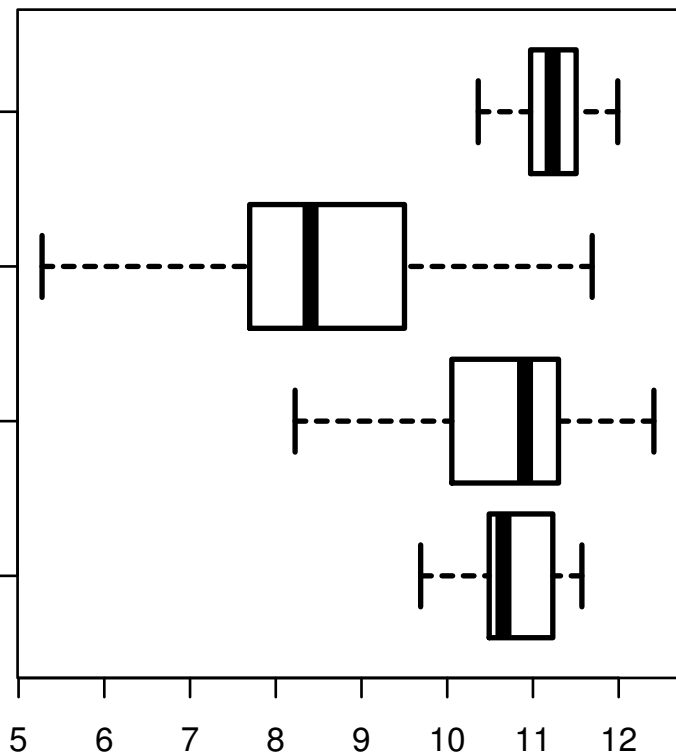


# ERBB3|2065

STOLOGICAL\_TYPE

THYROID  
PAPILLARY  
CARCINOMA -  
TALL CELL (>=  
50% TALL CELL  
PAPILLARY  
FEATURES)  
CARCINOMA -  
FOLLICULAR  
(>= 99%  
FOLLICULAR  
PATTERNED)  
THYROID  
PAPILLARY  
CARCINOMA -  
CLASSICAL/USUAL  
  
OTHER,  
SPECIFY



log2-EXPR  
Kruskal-Wallis P = 1.21e-31