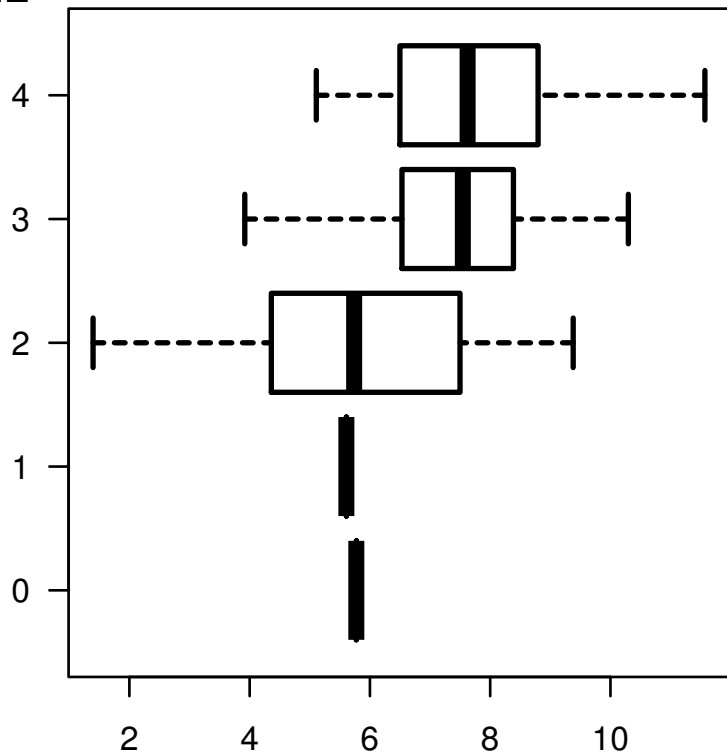


PATHOLOGY
T STAGE

HSA-MIR-99A



Spearman.Corr= 0.359, $P=2.43e-07$