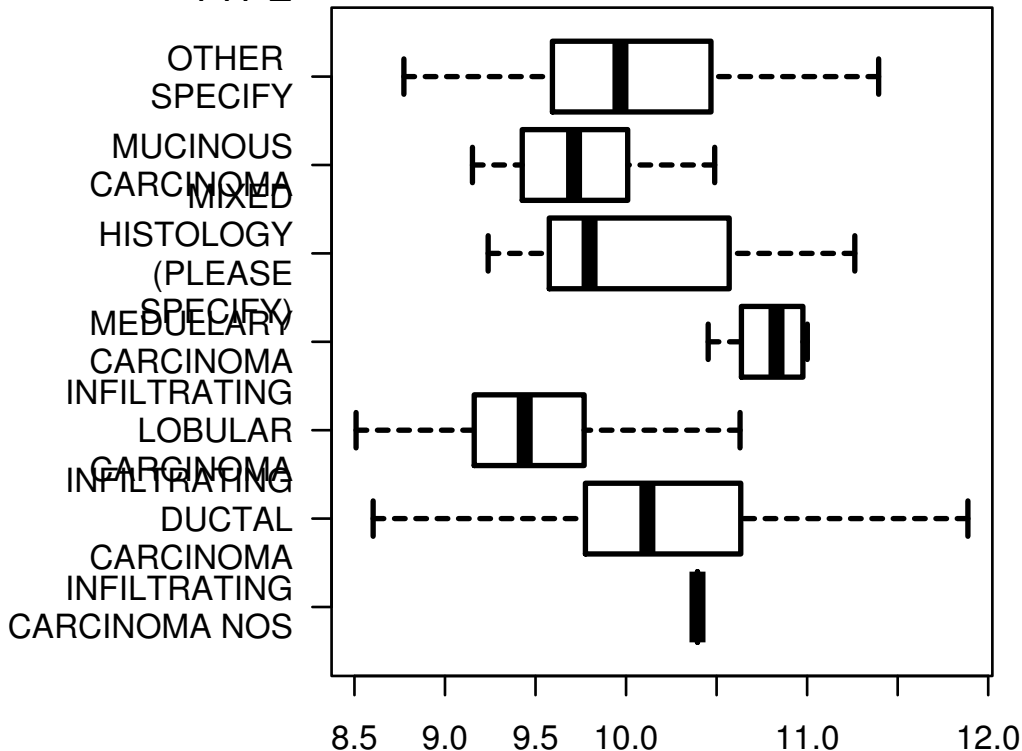


HISTOLOGICAL  
TYPE

PSMD12|5718



log2-EXPR  
Kruskal-Wallis P = 7.65e-37