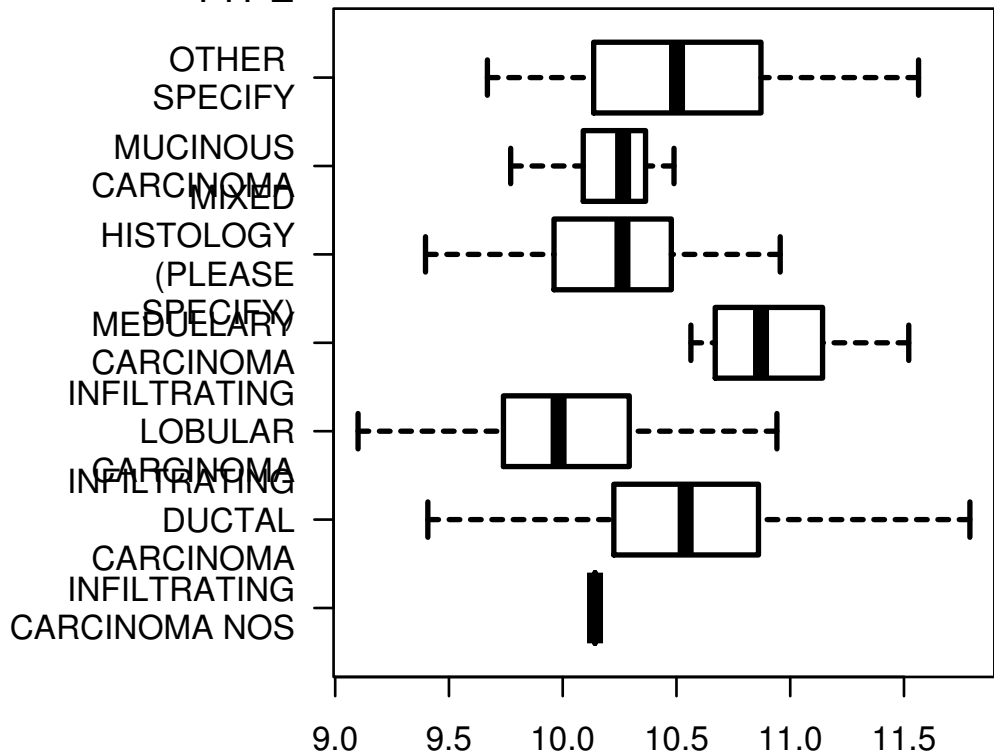


HISTOLOGICAL
TYPE

PSMD14|10213



log2-EXPR
Kruskal-Wallis P = 8.62e-37