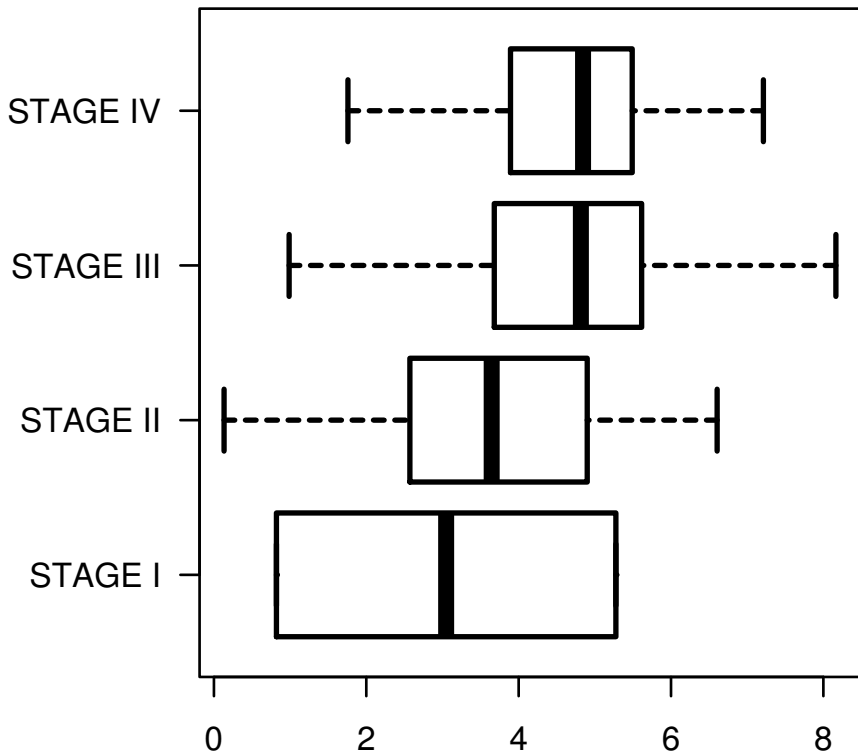


PATHOLOGIC_STAGE

HSA-MIR-214



log2-EXPR
Kruskal-Wallis P = 3.79e-08