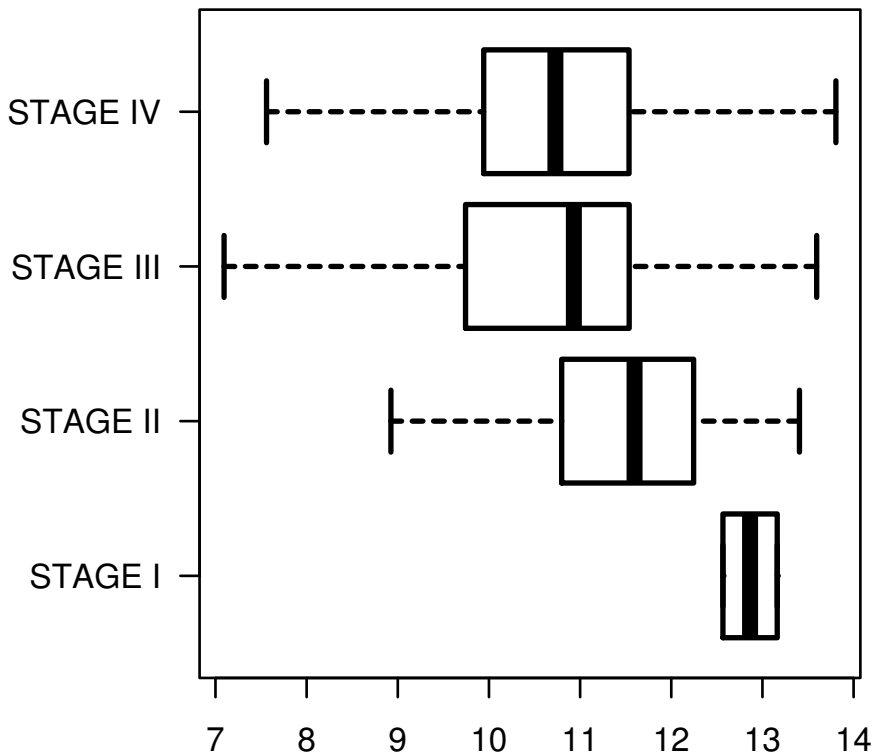


PATHOLOGIC_STAGE

HSA-MIR-141



log2-EXPR
Kruskal-Wallis P = 2.37e-08