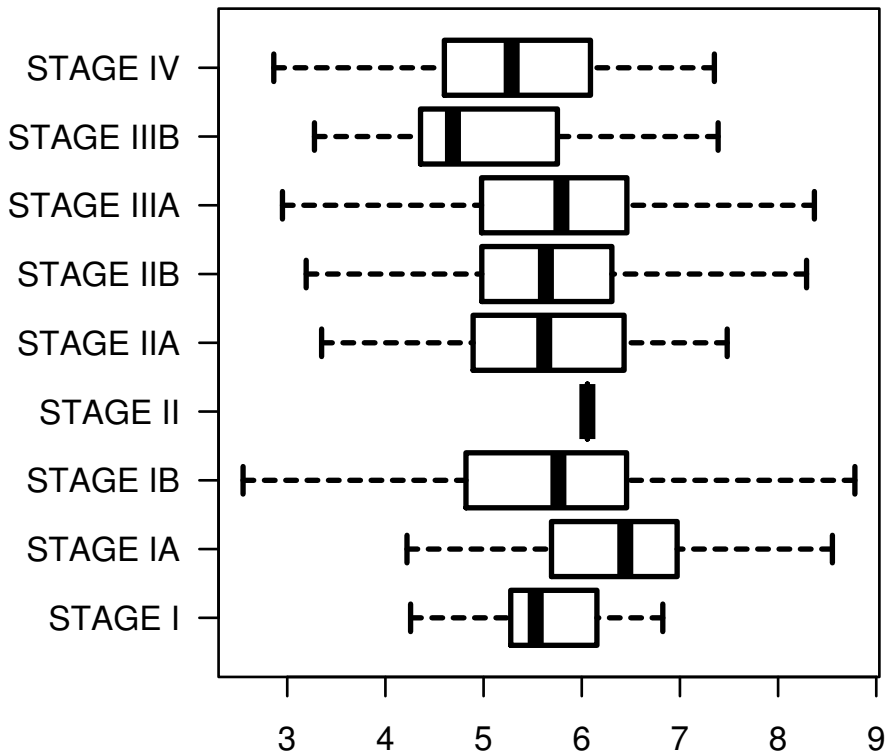


PATHOLOGIC_STAGE

RBP5|83758



Kruskal-Wallis P = 4.99e-08