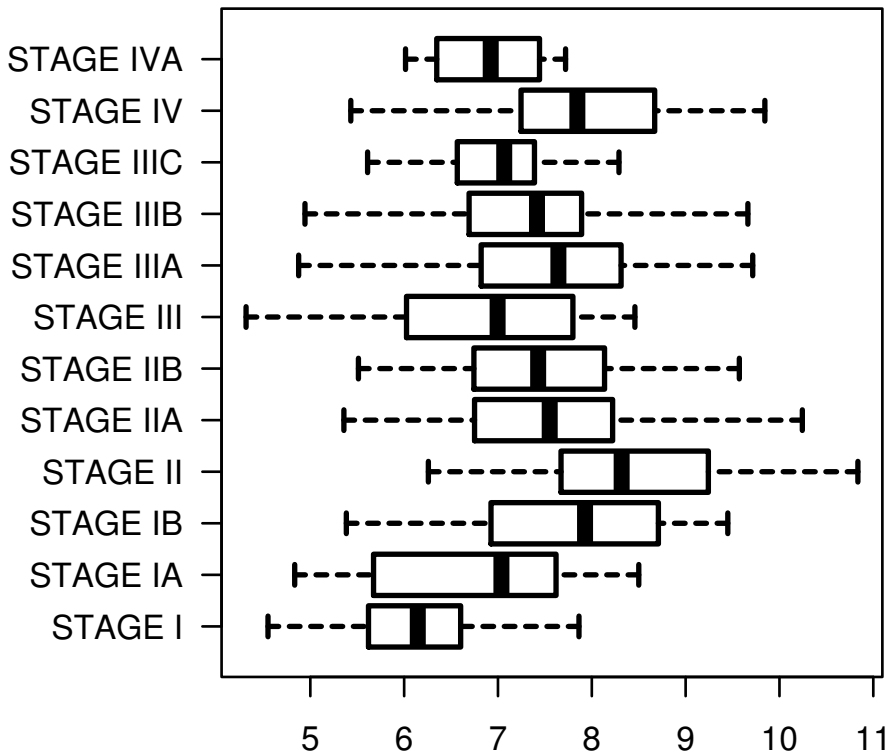


# HSA-MIR-134

PATHOLOGIC\_STAGE



Kruskal-Wallis P = 1.76e-10