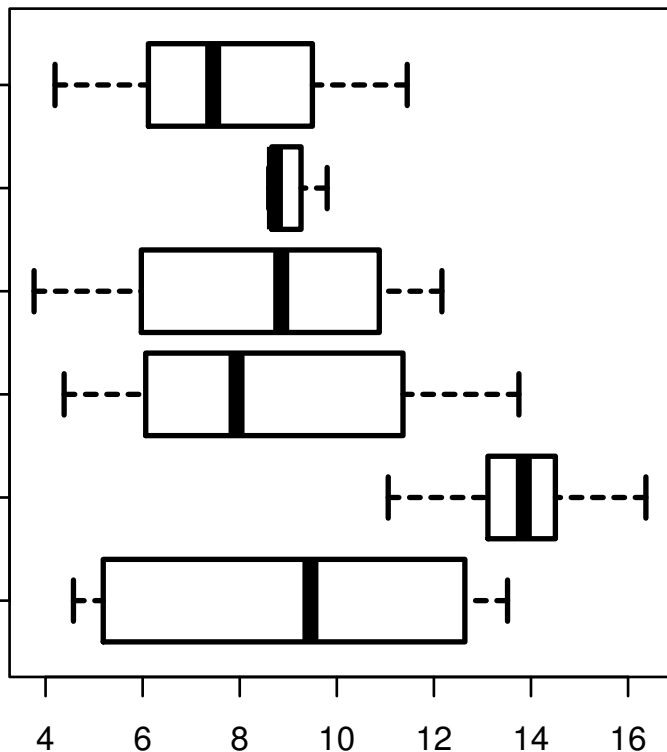


HSA-MIR-205

STOLOGICAL_TYPE

MUCINOUS
ADENOCARCINOMA
OF
ENDOCERVICAL
ENDOMETRIAL
TYPE
ADENOCARCINOMA
OF ENDOCERVIX
ENDOCERVICAL
TYPE OF
ADENOCARCINOMA
ENDOCERVICAL
ADENOCARCINOMA
OF THE USUAL
CERVICAL
TYPE
SQUAMOUS CELL
CARCINOMA
ADENOSQUAMOUS



log2-EXPR
Kruskal-Wallis P = 4.98e-22